

## Research Article

# Complications of Arteriovenous Fistula Created for Hemodialysis Access and Treatment Approaches

Serdar Demiral,<sup>1</sup> Ozlem Turkoglu,<sup>2</sup> Zafer Turkoglu<sup>3</sup>

<sup>1</sup>Department of General Surgery, Acibadem Hospital, Istanbul, Turkey

<sup>2</sup>Department of Radiology, Haydarpaşa Sultan Abdulhamid Han Training and Research Hospital, Istanbul, Turkey

<sup>3</sup>Department of Dermatology, Haseki Training and Research Hospital, Istanbul, Turkey

### Abstract

**Objectives:** Patients with chronic renal failure who are treated with hemodialysis need a patent arteriovenous fistula (AVF). This study was an analysis to determine the best approach to prevent complications and provide treatment.

**Methods:** In this retrospective study, a total of 437 AVF patients' medical records and postoperative epicrisis with 4 years of clinical follow-up were evaluated. The preferred method of anastomosis surgery was the end-to-side technique. Complications were divided into categories of early (seen within 48 hours), and late (after 48 hours).

**Results:** Of 437 patients, 288 (65.9%) were men, and the remaining 149 (34.1%) were women. The mean age was 46 years (range: 20-72 years). The locations of fistulas were snuffbox (n=42; 8.5%), radiocephalic (n=298; 60.9%), brachiocephalic (n=126; 25.6%), and brachio-basilic (n=25; 5%). Early complications were thrombosis (n=57; 69.5%), bleeding (n=14; 17%), and hematoma (n=11; 13.4%). Late complications observed were thrombosis/stenosis (n=25; 39.6%), venous hypertension (n=4; 6.3%), aneurysmatic dilatation (n=12; 19%), infection (n=6; 9.5%), bleeding/hematoma (n=7; 11.1%), arterial steal syndrome (n=4; 6.3%), congestive heart failure (n=1; 1.5%), seroma (n=2; 3.1%), and neuropathy (n=2; 3.1%). The most frequent of 145 total complications observed during the follow-up period was thrombosis (n=82; 16.7%).

**Conclusion:** The benefits of ultrasound assistance in both the control and treatment of bleeding was also a supportive measure for the management of complications, such as steal syndrome, as it can be used to develop the best treatment strategy by considering flow velocities, or in the case of venous hypertension, to detect central stenosis. Embelectomy with re-operation may be preferred in a case of thrombosis, rather than embelectomy alone, as it is a time-consuming procedure and was reported in our clinic to be less effective when a standalone procedure.

**Keywords:** Arteriovenous fistula, complication, thrombosis, treatment

**Cite This Article:** Demiral S, Turkoglu O, Turkoglu Z. Complications of Arteriovenous Fistula Created for Hemodialysis Access and Treatment Approaches. EJMO. 2017; 1(2): 76-81

The chronic renal failure (CRF) with its increasing number of patients carries a need for the correct vascular access during hemodialysis. Until time, three common methods have evolved for this purpose such as autogenous arteriovenous fistulas (AVFs), prosthetic arteriovenous grafts (AVG) and venous catheters.<sup>[1]</sup> AVFs are considered the most reliable long-term vascular access for

maintenance of hemodialysis (HD) in patients with CRF due to their good long-term patency and low complication rate.<sup>[2]</sup> AVFs require fewer interventions, are less susceptible to failure due to infection and thrombosis, and have been shown to improve patient survival. Therefore, for this commonly preferred surgery, its complications are in our main consideration.<sup>[3,4]</sup>

**Address for correspondence:** Ozlem Turkoglu, MD. Haydarpaşa Sultan Abdülhamid Han Egitim ve Arastirma Hastanesi, Radyoloji Klinigi, Istanbul, Turkey

**Phone:** +90 216 542 20 20 **E-mail:** ozlemkolcak@hotmail.com

**Submitted Date:** June 10, 2017 **Accepted Date:** August 14, 2017 **Available Online Date:** August 26, 2017

©Copyright 2017 by Eurasian Journal of Medicine and Oncology - Available online at [www.ejmo.org](http://www.ejmo.org)



**Table 1.** Early and late period complications with their AVF location

	Fistula location (n=491)		Early period <48 hrs (Grup 1, n=82)		Late period >48 hrs (Grup 2, n=63)		Total complication (n=145)	
	n	%	n	%	n	%	n	%
Snuff-box	42	8.5	15	35.7*	11	26.2*	26	61.9*
Radio-sefalic	298	60.9	48	16.1	26	8.7	74	24.8
Brachio-cephalic	126	25.6	12	9.5	16	12.6	28	22.2
Brachio-basilic	25	5	7	28*	10	40*	17	68*
Total	491		82	16.7	63	12.8	145	29.5

AVF: Arteriovenous fistula; \*p<0.05.

Our report was included a large series of AVF patients' medical records with their complication rates.

## Materials and Methods

For this retrospective study, 491 AVF patients were screened and 437 of them with sufficient records were chosen from the records of transplantation department Haydarpasa Numune Training and Research Hospital, İstanbul. The study was approved by the Local Ethics Committee. The medical documents were fulfilled with the data of patients' age, gender, underlying systemic diseases, operation epicrisis and clinical follow-up observations and the number of previous catheter trials. Fistula surgery was performed following standard technique starting 90 degrees of abduction of selected arm and 0.5% lidocaine injection as local anesthesia without epinephrine. The muscle dissection of arm was followed by arteriotomy, vein ligation, division and anastomosis by end to side technique with a fine continuous mono filament suture (6-0 or 7-0 polypropylene). In all patients vascular control was obtained with small vessel loops or Heifets Coronary dilator clamps were inserted to verify patency and diameter. Vessels were probed with the coronary dilators before the anastomoses was completed to confirm that not twisted. After vascular control was released and thrill felt over the fistula the skin was closed with an absorbable suture. The Doppler USG was on routine usage before and after the operation even in some cases during operation to check the flow. The AVF patency was assessed according to the standards of the Society of Vascular Surgery and the Society of Interventional Radiology. The Doppler (Esoata mylab 70 USG device) USG examination was performed by the radiologist. After surgery, some patients were needed MR (magnetic resonance) angiography besides the Doppler. When we diagnosed significant stenosis (>50%) of fistula, the Fogarty embolectomy procedure and in some conditions surgical revision was preferred as treatment.

## Statistical Methods

In this study, Chi-square and paired student t-test were

used as statistical analysis method. Statistical tests were performed with SPSSV10.0 software p<0.05 was considered to be statistically significant.

## Results

The study examined a total number of 437 patients in which 288 (65.9%) were male and 149 (34.1%) were female. These patients were between 20–72 years old ; mean age was 46 years old. In our clinic, the most preferred side for AVF surgery was the radiocephalic location (60.9%) and it was followed by brachio cephalic location (25.6%). The total number of early period complications was 82 and late period was 63. The total complication rate was highest in the brachiobasilic fistula (68%) which was followed by the snuff-box fistula (61.9%)

The early complications were primarily occurred in the snuff-box fistula (35.7%) and the late complications were in the brachiobasilic fistula (40%) Table 1.

When the early and late complications were cross tabled with fistula location thrombosis was the most common complication with 69.5% (0–48 hours) in the early period and 39.6% (>48 hours) in the late period (Table 2, 3). The early thrombosis was seen in the radio cephalic fistula (77%).

Other early complications were bleeding (17%) and hematoma (13.4%) which were mostly seen at brachiocephalic (33.3%) and brachiobasilic (28.5%) fistulas (p<0.05).

Thrombosis as a late complication was seen most in the brachiobasilic fistula (60%) and in the snuffbox fistula (54.5%) (p<0.05).

The late complications of arteriovenous fistula surgery were thrombosis (39.6%), aneurysm (19%), bleeding/hematoma (11.1%), infection (9.5%), venous hypertension (6.3%), arterial steal syndrome (6.3%), seroma (3.1%), neuropathy (3.1%) and congestive heart failure (1.5%). Venous hypertension and aneurysms were often observed in radiocephalic fistula while the rest of complications primarily observed in the brachiocephalic fistula (p<0.05).

**Table 2.** Early period complications with AVF location

	Location							
	Snuffbox		Radiocephalic		Brachiocephalic		Brachiobasilic	
	n	%	n	%	n	%	n	%
Tromboses (n=57, 69.5%)*	11	73.3*	37	77*	5	41.6	4	57.1
Bleeding (n=14, 17%)	3	20	6	12.5	4	33.3*	1	14.2
Hematoma (n=11, 13.4%)	1	6.6	5	10.4	3	25*	2	28.5*

AVF: Arteriovenous fistula; \*p<0.05.

**Table 3.** Late period complications with AVF locations

	Location							
	Snuffbox		Radiocephalic		Brachiocephalic		Brachiobasilic	
	n	%	n	%	n	%	n	%
Tromboses/stenoses (n=25, 39.6%)*	6	54.5*	11	42.3*	2	12.5	6	60*
Venous hypertension (n=4, 6.3%)	–	–	3	11.5	1	6.2	–	–
Aneurysmal dilatation (n=12, 19%)	2	18.1	8	30.7*	2	12.5	–	–
Infection (n=6, 9.5%)	1	9	1	3.8	3	18.7	1	10
Bleeding /hematoma (n=7, 11.1%)	2	18.1	1	3.8	3	18.7	1	10
Arterial steal syndrome (n=4, 6.3%)	–	–	1	3.8	3	18.7	–	–
Congestive cardiac failure (n=1, 1.5%)	–	–	–	–	1	6.2	–	–
Seroma (n=2, 3.1%)	–	–	–	–	–	–	2	20
Neuropathy (n=2, 3.1%)	–	–	1	3.8	1	6.2	–	–

AVF: Arteriovenous fistula; \*p<0.

The most common comorbidity associated with CRF was diabetes mellitus (DM) with 189 patients (43.2% p<0.05) and it was followed by hypertension of 58 patients (13.2%) (Table 4).

Thrombosis was the commonest complication of both early and late period and it was mostly seen with DM 65.8% (Table 5). We found out that thrombosis was least occurred brachiocephalic fistulas in both early and late period.

In 57 patients thrombosis happened in the early hours of AVF surgery and 32 of them had sufficient arterial flow. In those 32 patients after venotomy we applied the Fogarty's embolectomy and 2% heparin-saline solution without touching anastomoses (Fig. 1–3). We had successful result in 11 patients (34.3%). Unsuccessful 21 patients had new fistula from more proximal side. 25 patients without sufficient arterial supply were performed Fogarty's embolectomy with 2% heparin –saline solution additional to the re-anastomoses surgery. When we made re anastomoses our success was on 16 patients with 72.7%. In late period we approached to the patient in the same manner so that we first evaluated sufficiency of arterial supply and venous dilatation. Those 12 patients providing those criteria following venotomy were performed Fogarty's embolectomy with 2% heparin-saline solution. Only 2 of them were treated successfully (16.6%) and rest of 12 patients required a

**Table 4.** Comorbidities to CRF (total number of diseases: 437)

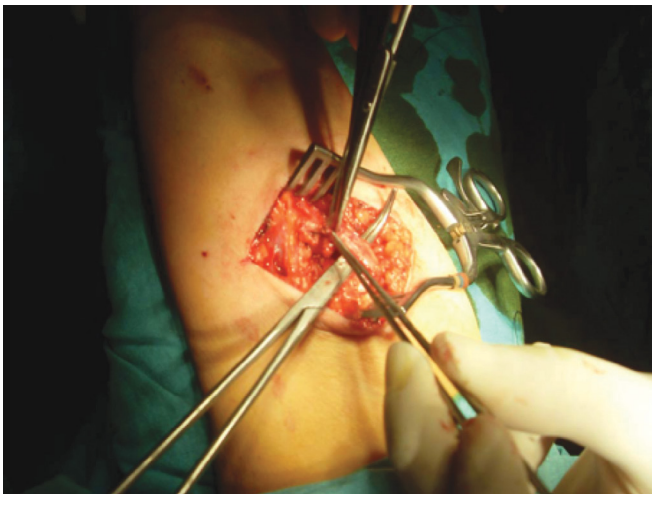
Comorbidity	n	%
Diabetes mellitus	189	43.2*
Hypertension	58	13.2
Coroner arterial disease	24	5.4
Peripheral vascular disease	23	5.2
Autoimmune diseases	12	2.7
Congenital /acquired thrombophilia	9	2
Total number	315	72

CRF: Chronic renal failure.

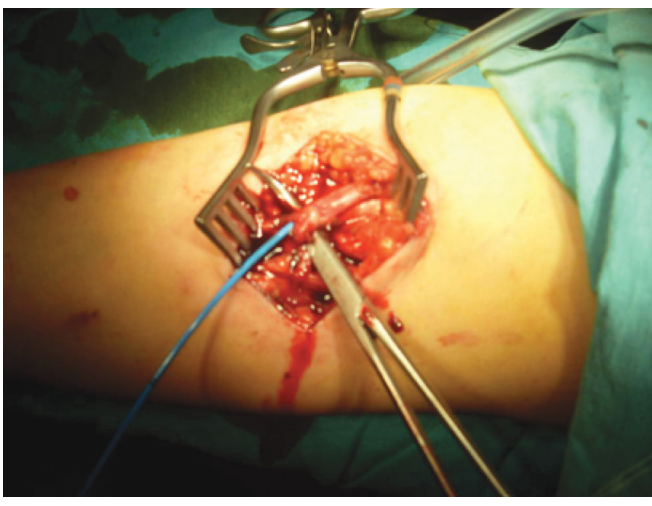
**Table 5.** Comorbidities to thromboses (total number of diseases: 82)

Comorbidities	n	%
Diabetes mellitus	54	65.8*
Hypertension	4	4.8
Coroner artery disease	3	3.6
Peripheral vascular disease	2	2.4
Autoimmune disease	5	6
Congenital /acquired thrombophilia	8	9.7*
Total	76	92.7

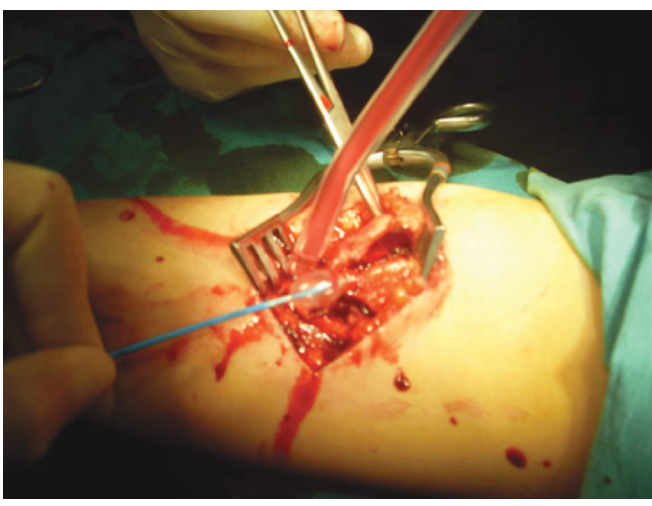
new fistula side from more proximal location. In 13 patients there was no flow in the anastomosis we canceled anastomotic line and 3 patients had success (23%).The mean age



**Figure 1.** AVF thrombosis and exploration.



**Figure 2.** Fogarty catheter thrombectomy.



**Figure 3.** Fogarty catheter thrombectomy.

for early thrombosis was 54 years (34–72) which was older than the mean age of study population  $p < 0.05$ . There wasn't statistically significant correlation between late thrombosis and age as seen as in the early thrombosis. Thrombectomy was applied to all patients whom applied emergently.

We treated those patients who had early bleeding and hematoma complications by close follow up and in necessity by supplying fresh frozen plasma. In case of gross hematomas, bleeding vessel was closed with 6–0 prolene suture. Hematoma was evacuated. In the early onset of bleeding our management was 100% successful. Our 7 patients who had bleeding due to venous punctures during dialyses were successfully treated.

In case of upper extremity venous hypertension, first we excluded central stenosis by the help of Doppler USG. Those 3 patients without central stenosis venous hypertension had recurrence in the following 3 months so that they had revision surgery.

Aneurysmal dilatation of AVF were observed on time interval of 3 to 42 months (mean time: 23 months) after fistula operation. In four patients, whose aneurysmal dilatation was accompanied by arm edema there was associated central stenosis diagnosed by Doppler USG. In those patients their fistulas were canceled. In 8 patients, without arm edema aneurysmal neck was constricted with prolene suture. On those patients, we didn't observe recurrent aneurysm development through follow up period.

Those patients who were developed infection were treated by broad spectrum medical antibiotics. None of the patient developed abscess formation.

In arterial steal syndrome those four patients were staged by Doppler USG. In one patient with the stage I there was retrograde inflow of blood into access during diastole requiring no treatment. In three patients who developed peripheral ischemia (stage III) and had high flow associated (400 ml/min) steal syndrome, we performed access banding to create a narrow vein segment within the access, close to anastomosis by non-absorbable sutures. After access banding two patients had the same problem so that we canceled their fistula. Our success rate for access banding was 33.3%.

In other complications such as in congestive heart failure we preferred to cancel the fistula. In two patients with seroma which was aspirated by cannula fistula patency was maintained. In 2 patients with neuropathy we managed the patency of fistula only by clinical follow up.

## Discussion

As we already know the principles of AVF surgery have been considered upper extremity, non dominant arm and

as distal location as available.<sup>[5]</sup> Regardingly, among the types of fistula most preferred one is radio cephalic (Brescia-Crimino) approach that became almost as standard type of fistula surgery after 1966.<sup>[4]</sup>

Another factor which affects our choice of fistula is accompanying diseases and results of previous catheter trials. Our study population were operated also according to basic principles and radio cephalic approach was our common choice as well. By looking our data base, this technic was performed in high number (60.9%) and it resulted with an acceptable level of complication rate (24.8%) by supporting the literature about its safety as well.

In patients with significant obesity and chronic diseases such as diabetes and atherosclerosis creating vascular access is not easily available<sup>[6]</sup> besides high numbers of puncture application to their superficial venous structures or disease' progress itself on small caliber vasculature, may lead more proximal fistula trials. Diabetics constituted 49% of our study patients, the deficiency of distal peripheral venous structures was leading reason for us to prefer proximal location in this population.

We encountered the same results as literature that thromboses were leading complication. Iyem et al, reported the same highest complication rate of thromboses in a broad study population.<sup>[7]</sup> When we consider early complication rates we saw that high thrombosis rates especially in radiocephalic location were associated with anatomical limitations of surgery in this area where also most of bleeding and hematoma formations occurred. Radiocephalic location was announced in the literature as most common location for thrombosis in early period<sup>[8]</sup> as well. Radiocephalic location being most common choice of surgeons for fistula creation causes reasonable high rates for complications like hematoma and bleeding so that induces early thrombosis.

However in late period after 48 hours from surgery, thromboses was forming more proximally. That was due to accompanying disease such as diabetes in addition to reasons like bleeding, hematoma, seroma. With the knowledge of disease' effects on vascular and clotting system we realized that diabetes was showing most common comorbidity with thromboses. Different from the literature we presented statistically significant location for later thromboses after AVF surgery.

Bleeding and hematoma were two complications apart from thromboses. We had emergent approach in case of bleeding and hematoma so that we prevented early thromboses. Literature as well stress out the importance of emergent approach to those patients.<sup>[9]</sup> Here the USG Doppler provided the information about exact source for

bleeding, size of hematoma and fistula patency. In the literature there have been some studies clarifying the benefits of the Doppler USG assistance for the long time patency of fistula.<sup>[10]</sup>

The steal syndrome was another complication we used the advantage of Doppler USG by seeing resultant flow characteristics which is main determinant of effectiveness of treatment.<sup>[11]</sup> The USG was supportive for treatment by showing flow velocities or in the venous hypertension to detect central stenosis as well.

In summary, we discussed the thrombosis which is the most common complication of AVF surgery in detail. Different from the literature we reported complication and thrombosis 48 hours after surgery. Also we realized a technical detail such that direct venotomy and Fogarty thrombectomy technique without touching the anastomosis were seen to be inferior to those of Fogarty thrombectomy and re-anastomosis technique (for early and late period, 34.3%–72.7% and 16.6%–23% respectively). Detailed analyses on complication rates we would like to share this document.

#### Disclosures

**Ethics Committee Approval:** The study was approved by the Local Ethics Committee.

**Peer-review:** Externally peer-reviewed.

**Conflict of Interest:** None declared.

#### References

1. Surratt RS, Picus D, Hicks ME, Darcy MD, Kleinhoffer M, Jendrisak M. The importance of preoperative evaluation of the subclavian vein in dialysis access planning. *AJR Am J Roentgenol* 1991;156:623–5. [\[CrossRef\]](#)
2. Enzler MA, Rajmon T, Lachat M, Largiadèr F. Long-term function of vascular access for hemodialysis. *Clin Transplant* 1996;10:511–5.
3. Vascular Access 2006 Work Group. Clinical practice guidelines for vascular access. *Am J Kidney Dis* 2006;48 Suppl 1:S176–247.
4. Brescia MJ, Cimino JE, Appel K, Hurwich BJ. Chronic hemodialysis using venipuncture and a surgically created arteriovenous fistula. *N Engl J Med* 1966;275:1089–92. [\[CrossRef\]](#)
5. Elwakeel H, Elalfy K. Vascular Access for Hemodialysis - How to Maintain in Clinical Practice. In: Suzuki H, editor. *Hemodialysis*. InTech: 2013.
6. Kherlakian GM, Roedersheimer LR, Arbaugh JJ, Newmark KJ, King LR. Comparison of autogenous fistula versus expanded polytetrafluoroethylene graft fistula for angioaccess in hemodialysis. *Am J Surg* 1986;152:238–43. [\[CrossRef\]](#)
7. Iyem H. Early follow-up results of arteriovenous fistulae creat-

- ed for hemodialysis. *Vasc Health Risk Manag* 2011;7:321–5.
8. Hong SY, Yoon YC, Cho KH, Lee YH, Han IY, Park KT, et al. Clinical Analysis of Radiocephalic Fistula Using Side-to-side Anastomosis with Distal Cephalic Vein Ligation. *Korean J Thorac Cardiovasc Surg* 2013;46:439–43. [\[CrossRef\]](#)
  9. Spergel LM, Ravani P, Roy-Chaudhury P, Asif A, Besarab A. Surgical salvage of the autogenous arteriovenous fistula (AVF). *J Nephrol* 2007;20:388–98.
  10. Ferring M, Claridge M, Smith SA, Wilmink T. Routine preoperative vascular ultrasound improves patency and use of arteriovenous fistulas for hemodialysis: a randomized trial. *Clin J Am Soc Nephrol* 2010;5:2236–44. [\[CrossRef\]](#)
  11. Mickley V. Steal syndrome—strategies to preserve vascular access and extremity. *Nephrol Dial Transplant* 2008;23:19–24.